



Encino

Santa Monica

Valencia

Thousand Oaks

Century City

(877) 3-RETINA

## Case of the Month – May 2020

Presented by Christian Sanfilippo, MD

A 24 year old female presented with a 1 week history of flashes and “spots” in her vision in the right eye. The symptoms coincided with an upper respiratory tract infection that she had developed a few days prior to the onset of visual changes. She had no past medical history, no past ocular history, and her only medication use was an oral contraceptive. Vision was measured as 20/20 without correction and intraocular pressures were normal. Her anterior segment examination was unremarkable with the exception of occasionally anterior vitreous cells in the right eye. Posterior segment imaging are shown below.

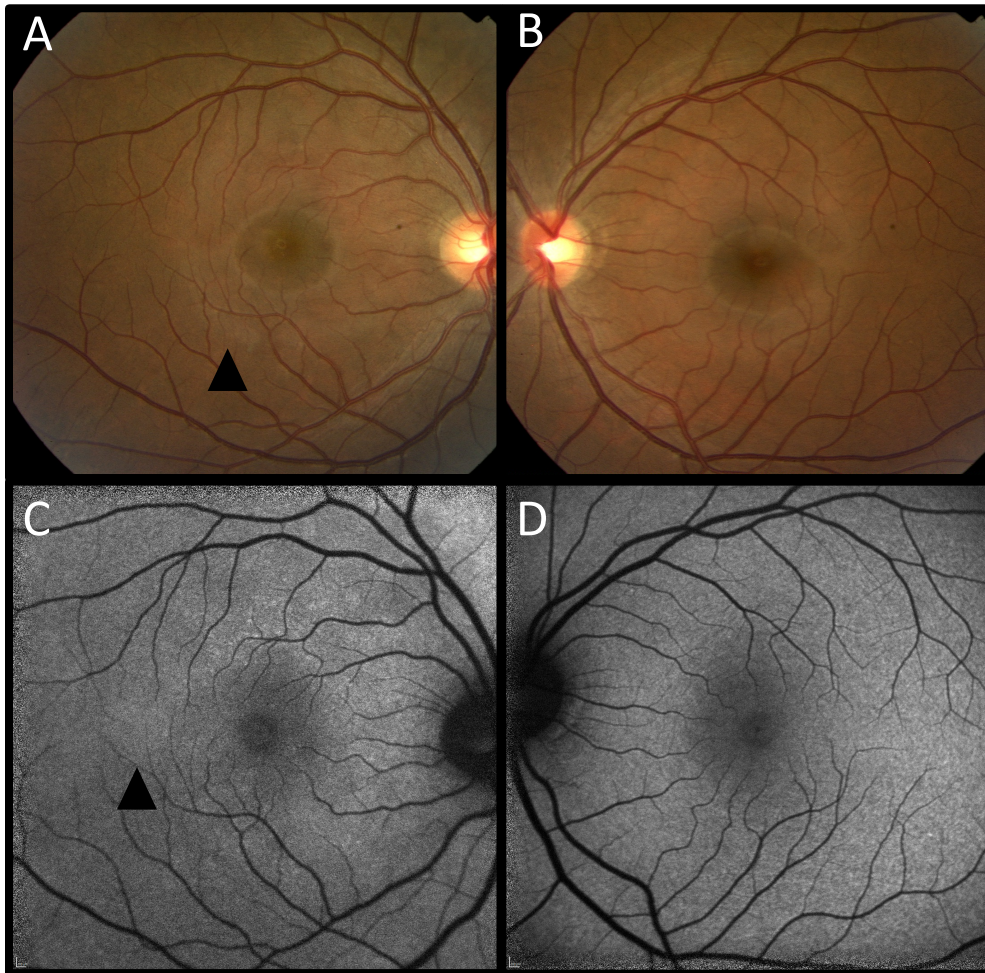


Figure 1: A. Color fundus photo of the right eye shows subtle, splotchy whitening in the perifoveal region (arrowhead). B. Color fundus photo of the left eye is normal. C. Fundus autofluorescence imaging of the right eye shows mild hyper-autofluorescence, in the same perifoveal region (arrowhead). D. Fundus autofluorescence of the left eye is normal.

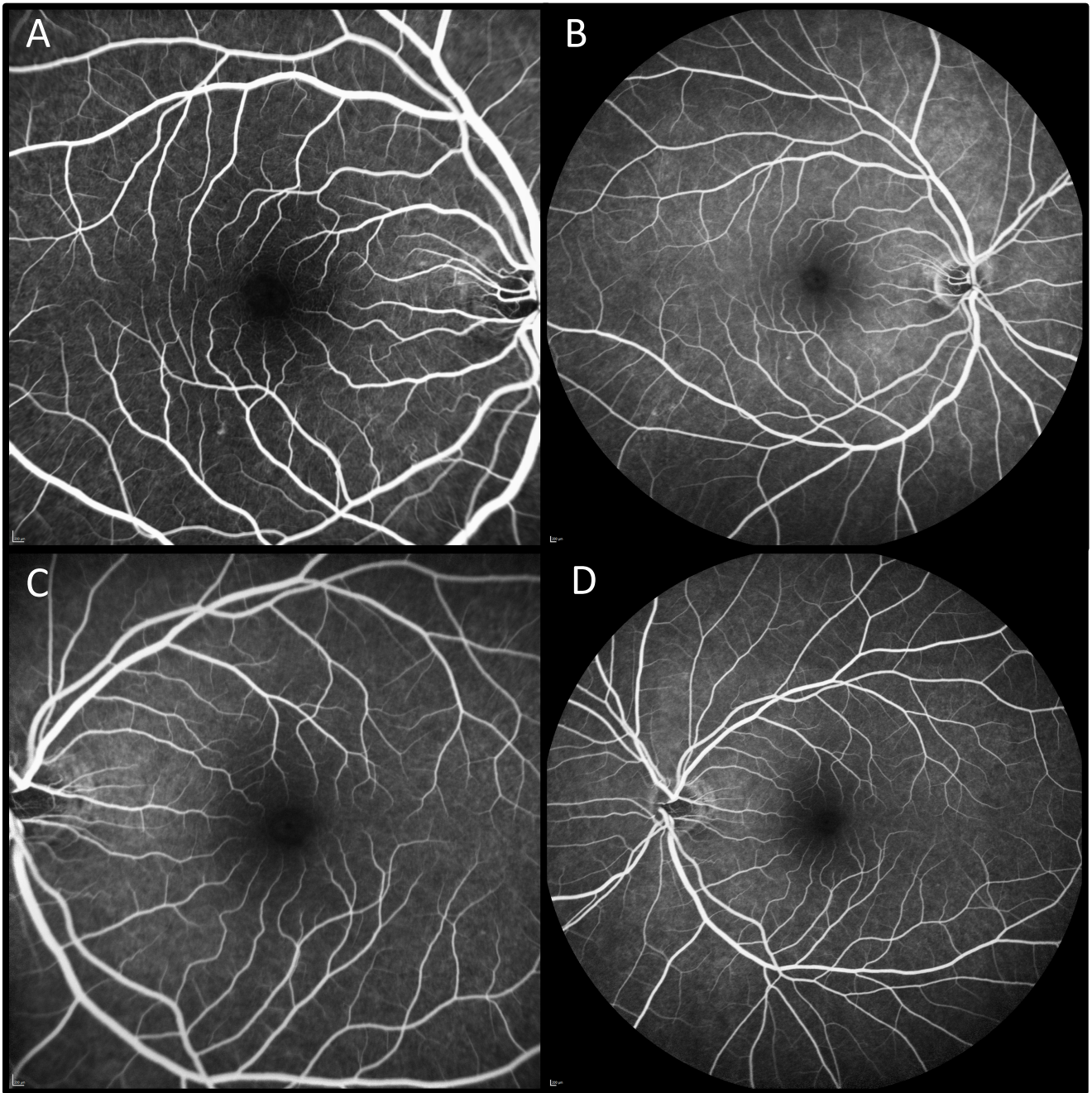


Figure 2: A. Early phase fluorescein angiography of the right eye was essentially normal. B. Late phases of the right eye showed a non-specific and mild increase in non-specific hyper-fluorescence as well as mild hyper-fluorescence within the fovea. In comparison, early (C) and late (D) phase images of the left eye are normal.



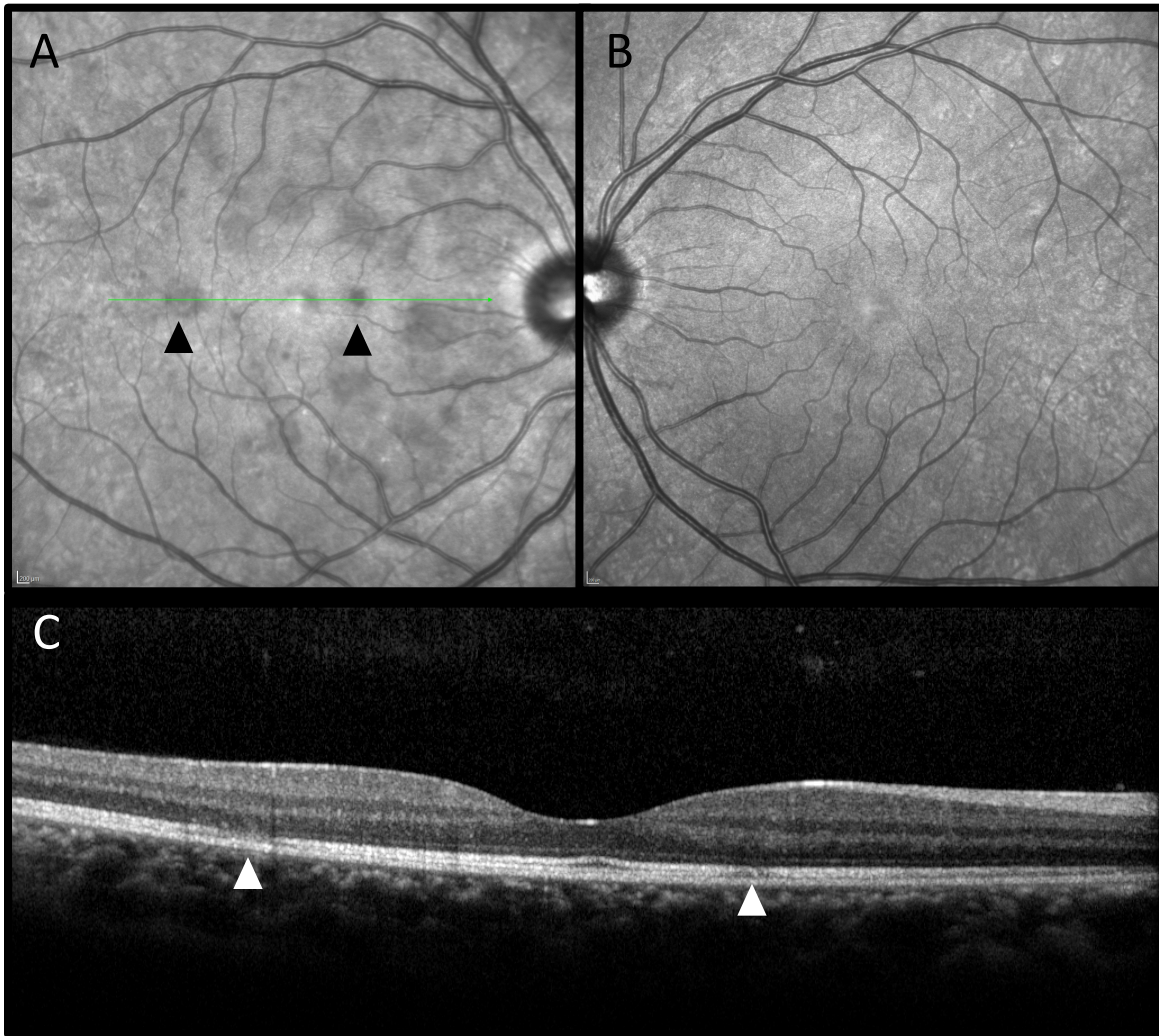
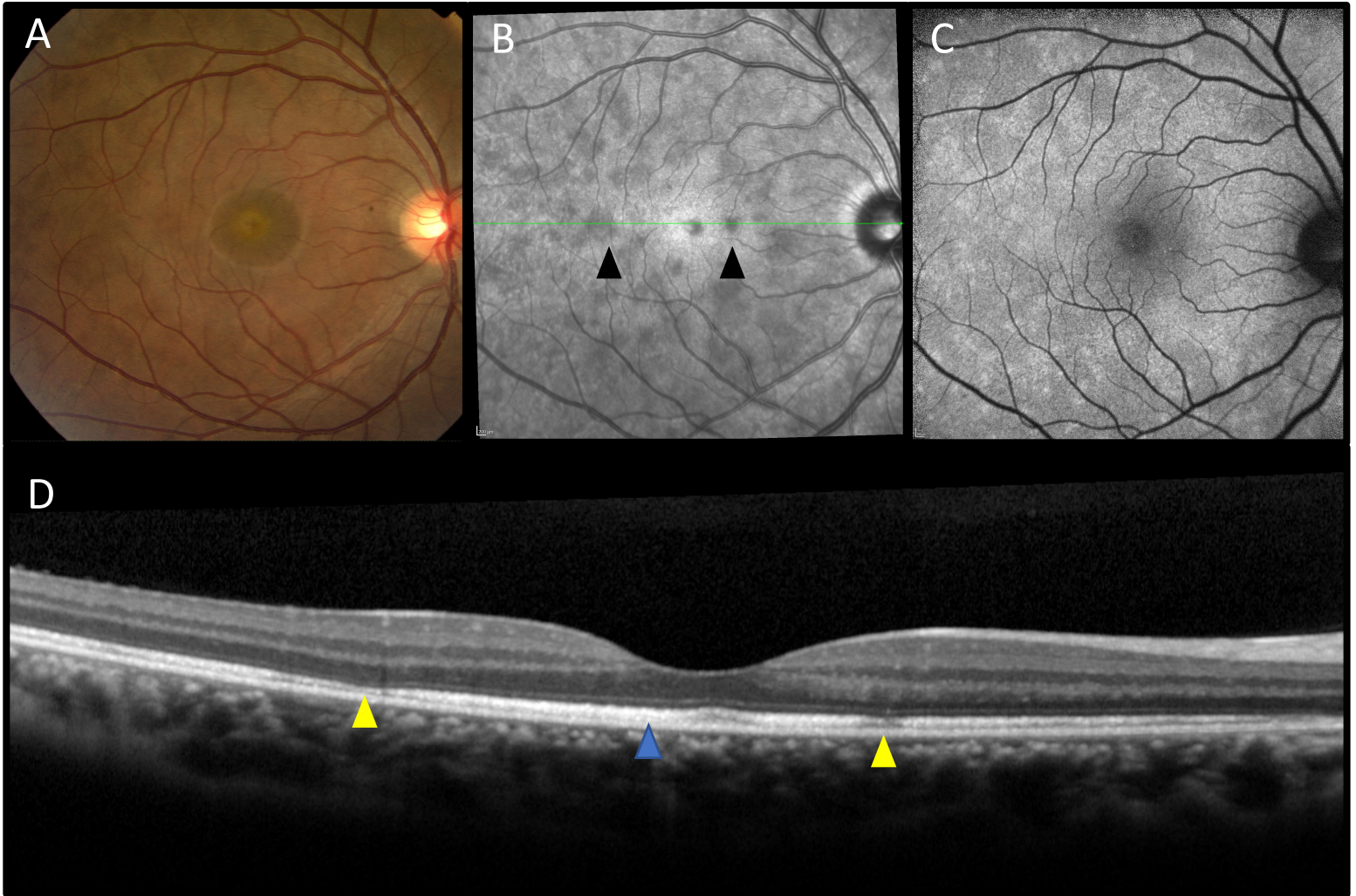


Figure 3: A. Near infrared imaging shows drastic hypo-reflective lesions scattered throughout the macula in the right eye (arrowheads). This contrasts to the normal near infrared image of the left eye (B). C. SD-OCT line scan obtained through the fovea and two of the hypo-reflective lesions localizes the defect to the ellipsoid zone with mild hyper-reflectivity extending into the outer nuclear layer (arrow).

**Differential Diagnosis:** Acute macular neuroretinopathy (AMN), multiple evanescent white dot syndrome, APMPE, infectious chorioretinitis, birdshot chorioretinopathy

**Clinical Course:**

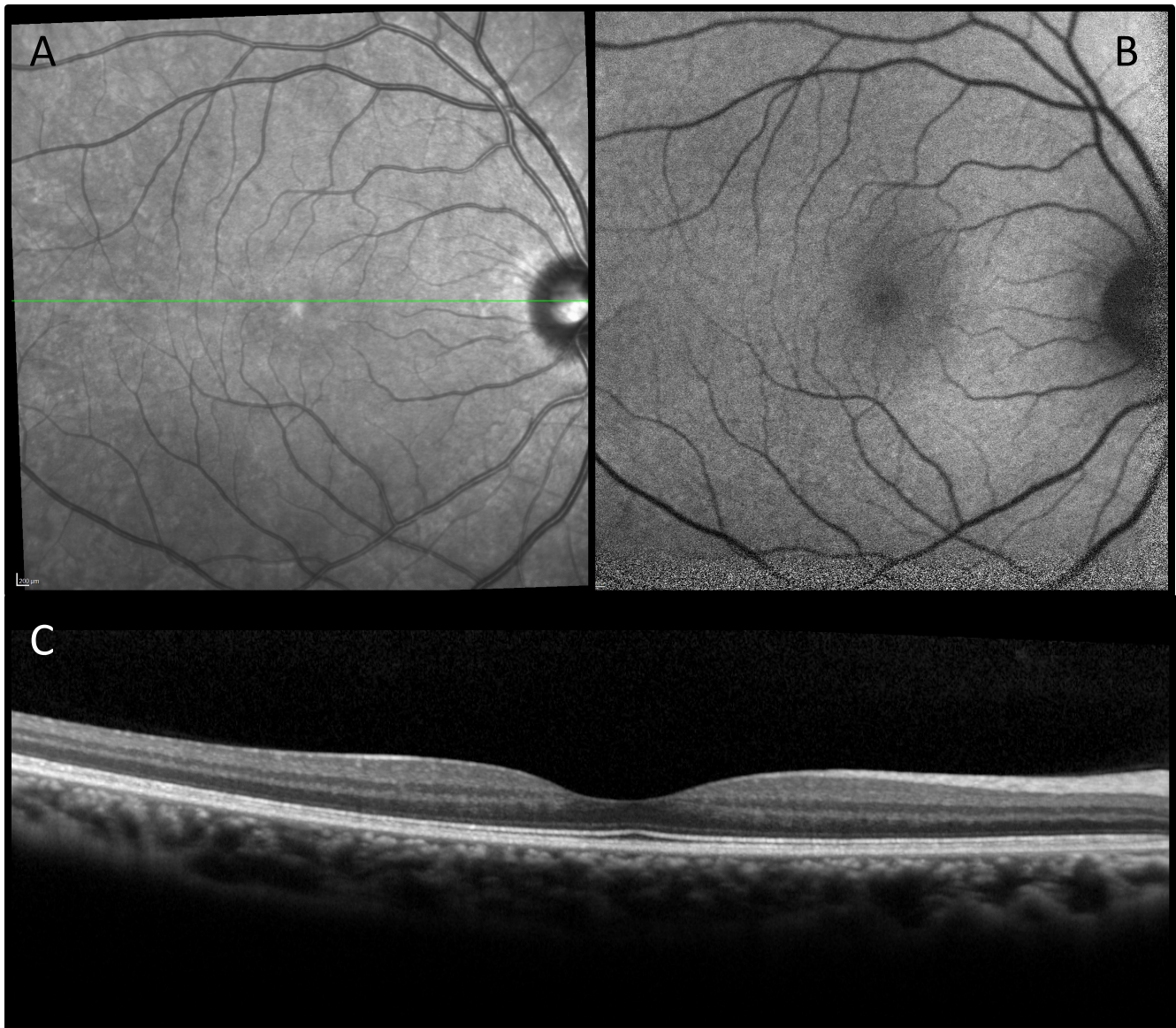
Based on imaging and clinical context, the patient was given a preliminary diagnosis of MEWDS. However, because the findings on autofluorescence and fluorescein angiography were very mild in comparison to the dramatic changes visible on near-IR imaging (which is typical of acute macular neuroretinopathy), AMN was also considered. The patient returned 1 week later for repeated examination and diagnostic studies which are shown below.



**Figure 4:** A. Color fundus photo at 1 week follow up shows a granular fovea, and more prominent grey-white lesions within the macula. B. Near IR image of the right macula show more numerous hypo-reflective lesions (arrowheads). C. Autofluorescence now shows diffuse, scattered hyper-autofluorescence dots. D. SD-OCT through the fovea and the same pericentral lesions shown in Figure 3 shows persistent ellipsoid defects (yellow arrowheads). Additionally, there is now diffuse thickening of the ellipsoid band (blue arrowhead).

Follow up examination and diagnostic studies confirmed the diagnosis of MEWDS. The patient was offered reassurance that her symptoms would improve with observation. By her two month follow up, she no longer noticed the spots in her vision, and acuity remained 20/20. Imaging is shown below.





**Figure 5:** At 2 month follow up, near-IR images (A), autofluorescence (B) and SD-OCT (C) showed significant improvement with near normalization.

### **Discussion:**

Multiple evanescent white dot syndrome (MEWDS) is a rare, typically unilateral retinopathy which generally affects young adults, most commonly in their 20's. These patients are more often female (~75%) and myopic. Presenting symptoms typically include acute onset of photopsias, blurred vision and "spots" in the vision affecting one eye. These symptoms are frequently either preceded by, or concurrent with a flu-like illness.

Examination findings can be subtle, and variable. Visual acuity may range from 20/20, as in our case, to 20/300 at presentation. Anterior segment examination is typically unremarkable, but mild iritis has been reported. The posterior segment findings may be difficult to detect without multi-modal imaging. Findings most often include mild vitreous cells, optic nerve swelling, numerous subtle grey-white dots centered throughout the posterior pole with less extensive peripheral involvement, and a "granular" fovea (as seen in figure 4A). Because of the self-limited, and rapidly resolving nature of the disease in most cases, these findings may change from week to week. This is clearly demonstrated in our case which showed worsening findings over the first week, followed by complete resolution. This can make diagnosis more challenging depending upon the point in the disease course when the patient presents.

Multi-modal imaging is extremely important, and in most cases diagnostic. Classically, fluorescein angiography will show early and late hyper-fluorescence of the dots, in a “wreath-like” pattern. Our case, did not show this typical pattern, though it is likely that had the fluorescein angiogram been repeated at the week one visit when clinical findings were more apparent, the test would have been more striking. Indocyanine green angiography (ICGA) can also be quite helpful, and will often reveal many more lesions than were otherwise apparent. ICGA classically shows larger hypo-fluorescent lesions termed “spots” which are seen underlying the white dots highlighted by the other imaging modalities. Fundus autofluorescence and near-IR imaging are both non-invasive tools which can highlight the lesions. As our case suggests, different imaging modalities may be more or less helpful depending upon their timing relative to the disease onset. Therefore, when diagnosis is in question, repeated imaging can be very helpful.

OCT imaging has helped elucidate much of what is known about the pathogenesis of this rare disease. SD-OCT images localize the lesions to the outer retina. Specifically, the ellipsoid band, representing the junction between the photoreceptor inner and outer segments, is disrupted. This has led some authors to propose that MEWDS represents a primary disease of the photoreceptors. Others have suggested that the disease first causes retinal pigment epithelial cell dysfunction with secondary damage to the photoreceptors. While much has been written regarding OCT findings in MEWDS, a detailed discussion of these findings is beyond the scope of this review.

Despite its first description nearly 4 decades ago, as with most of the white dot syndromes, we still do not completely understand the etiology of MEWDS. The concurrence of flu-like symptoms at or around the time of onset of visual symptoms suggests that MEWDS may be part of a viral syndrome, or perhaps an auto-immune phenomenon triggered by such environmental factors. Fortunately, MEWDS is a self-limited disease which rarely recurs. Patients typically recover their baseline vision, and scotoma resolve over the course of 3 to 10 weeks without treatment. Therefore, these patients are best managed with observation and reassurance.

### Take Home Points

- MEWDS is a rare, unilateral retinopathy which most commonly affects young myopic females
- The diagnosis is made on the basis of clinical examination and multi-modal imaging
- MEWDS is self-limited and the majority of patients experience resolution of their symptoms over a 3-10 week period, without treatment.



Thomas Hanscom



Robert Engstrom



Hajir Dadgostar



Amir Guerami



Christian Sanfilippo



Stavros Moysidis