



Encino

Santa Monica

Valencia

Thousand Oaks

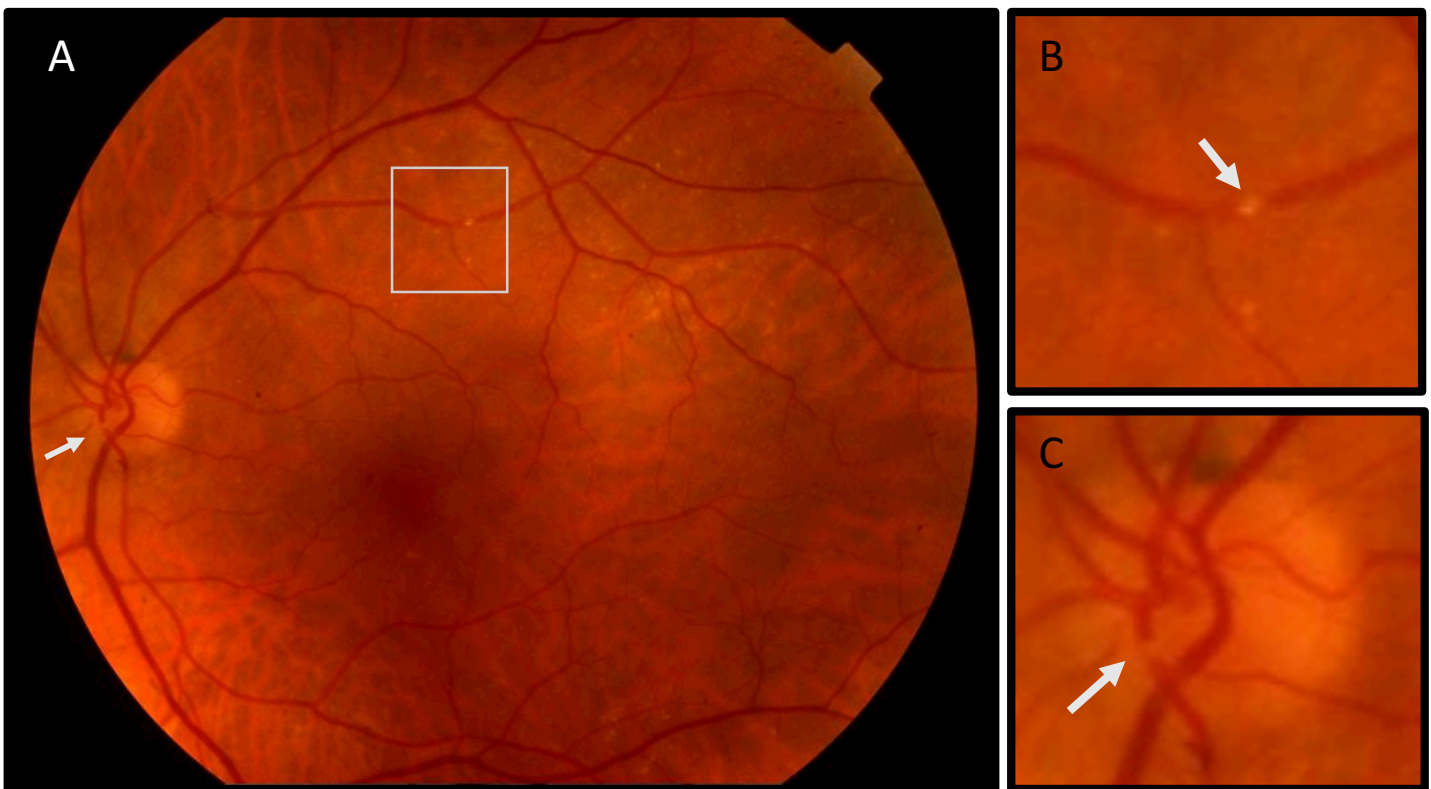
Century City

(877) 3-RETINA

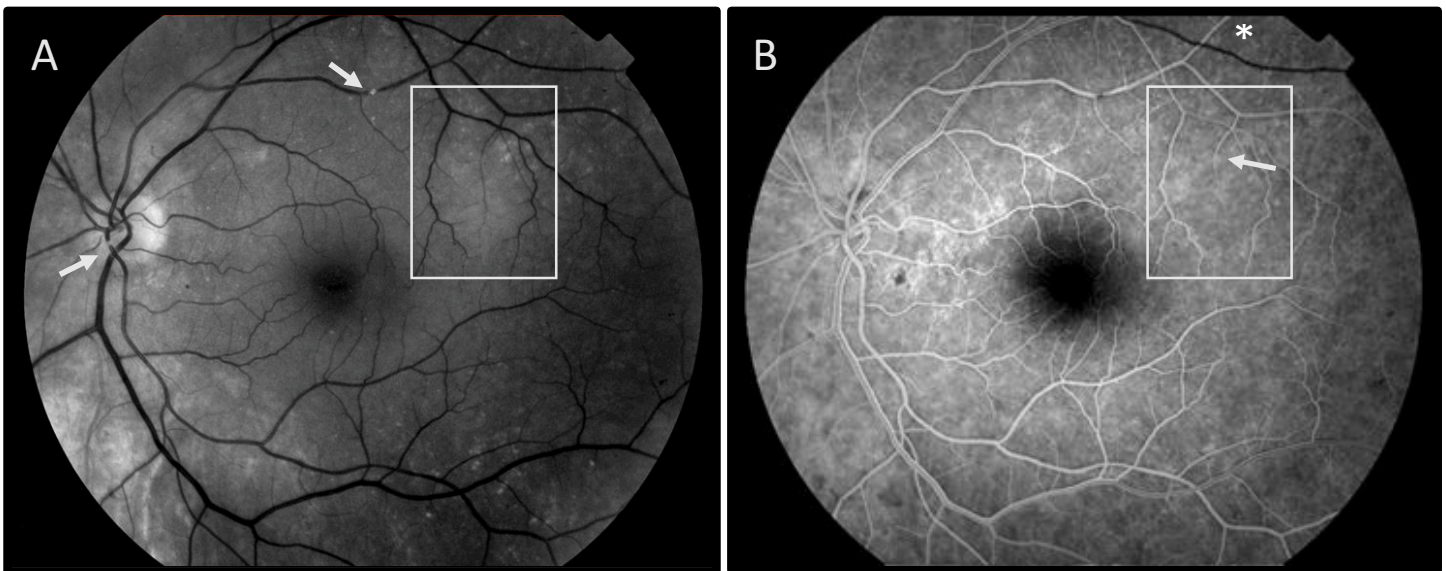
## Case of the Month – April 2019

Presented by Christian Sanfilippo, MD

A 69 year-old man with a past medical history of hypertension and hyperlipidemia presented for evaluation of visual loss in the left eye described as a graying out of his central vision lasting about 8 minutes, which resolved leaving a persistent “gray spot” in his nasal visual field. The event occurred approximately 2 weeks prior to his presentation. His ocular history was significant for a retinal tear repaired by laser retinopexy in the right eye 1 year prior. Visual acuity was 20/20 and 20/25-2 in the right and left eyes respectively. Intraocular pressures were within normal limits. The anterior segment examination was remarkable only for mild cataract in each eye. Fundus imaging of the right eye was unremarkable. The left fundus is shown below.



**Figure 1:** A. Color fundus photo of the left eye shows two intra-arteriole emboli, one within the inferior arcade at the level of the optic nerve head (arrow) and the second within the superotemporal arcade (box). B. Magnified view of the superotemporal arteriole more clearly shows the embolus (arrow). C. Magnified view of the optic nerve shows the embolus (arrow).



**Figure 2:** **A.** Red free image of the left eye highlights the intra-arteriole emboli (arrows) as well as an area of retinal whitening, not clearly seen on the fundus imaging (box). This region corresponds to the retina surrounding an attenuated arteriole which is barely visible on fluorescein angiogram (**B**, arrow). **B.** Fluorescein angiogram shows delayed filling of the superotemporal venous arcade (asterisk) indicating segmental slowing of the arteriovenous phase. Note the attenuation of the distal arteriole within the highlighted box, corresponding to the area of whitening (arrow).

### Clinical Course:

The patient was diagnosed with two embolic branch retinal artery occlusions, with symptoms consistent with initial amaurosis fugax. Review of systems with special attention to neurologic symptoms was negative, and neurologic examination was normal. The patient was referred immediately to the nearest stroke center for an emergent stroke workup. MRI brain revealed an acute left hemispheric infarct and carotid ultrasound showed 50-60% occlusion of the left internal carotid artery. The patient was admitted to the neurology service for further testing and optimization. In consultation with the vascular surgery service, the carotid occlusive disease was felt to be the causative source of emboli and therefore, the patient underwent carotid endarterectomy. Follow up ophthalmologic examination 3 weeks later showed stable findings, without recurrence of the patient's previous central transient visual loss.

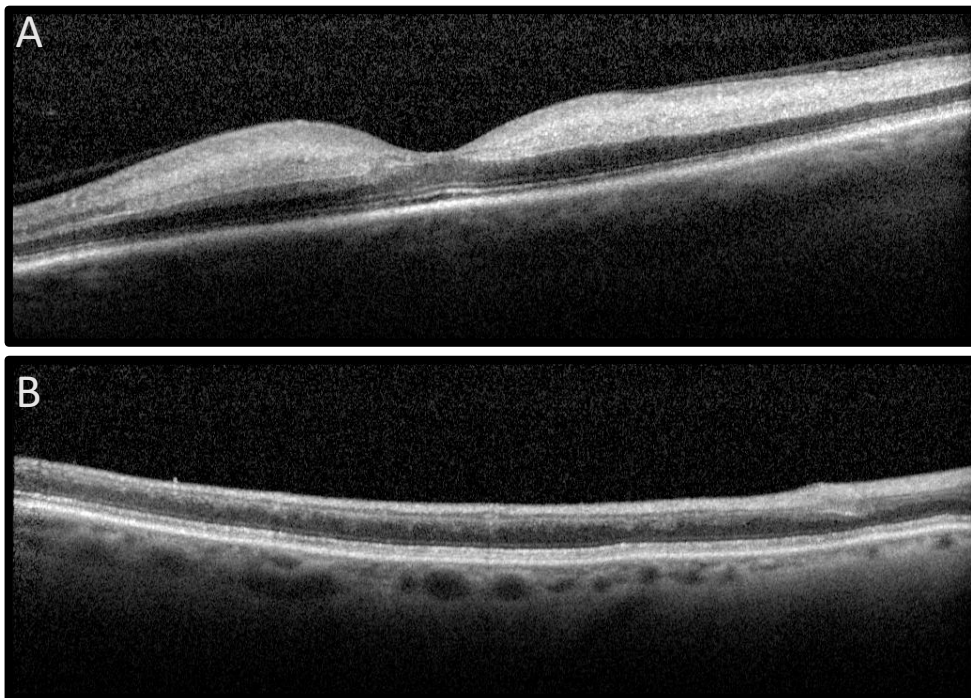
### Discussion:

Retinal arterial occlusions are rare, but serious ocular events which often lead to permanent visual impairment and can indicate the presence of a life threatening medical condition. They are defined by the interruption in blood flow to any of the retinal arterioles which causes rapid retinal cell death and permanent visual loss. This is most often the result of an embolic event, but may also be caused by vasculitis (as in Giant Cell Arteritis) or severe vasospasm. The reported incidence of retinal artery occlusion varies by population from 1 to 8.5 cases per 100,000 people. The incidence increases with age, with a mean presentation in the early 60's, and a peak incidence at 80 years old. Like stroke, there is a slightly higher risk in men as compared to women.

Diagnosis relies heavily upon history and clinical examination. Symptoms vary widely depending upon the vascular distribution affected and whether the occluded vessel reperfuses prior to retinal cell death. Ophthalmic artery occlusions, which affect both the choroidal and retinal circulation, are the most severe, and often present with visual acuities in the hand motions to light perceptions range. On the other end of the spectrum, are patients with small branch retinal artery occlusions which may present with a subtle visual field defect, or in some cases, remain completely asymptomatic. Patients may also describe transient episodes of graying out of part or all of their visual field, corresponding to intermittent interruption of blood flow followed by rapid reperfusion prior to cellular injury. This results in amaurosis fugax. Our patient likely experienced a

transient interruption in blood flow to the central retinal artery, which fortunately reperfused as the embolus travelled downstream, lodging in smaller branch retinal arteries.

Exam findings vary depending on timing of the examination in relation to when the obstruction occurred. The examination may, in fact, appear completely normal at the onset of symptoms, or in cases of amaurosis. However, with persistent occlusion, the classic findings of retinal arteriole boxcarring, whitening of the affected retina and a cherry red spot (in central retinal artery occlusion) will appear. An intra-arteriole plaque may sometimes be found (as in our case), most often lodged at an arteriole bifurcation point. When present, this confirms an embolic etiology of the occlusion. Diagnostic imaging can be very helpful, especially when clinical examination findings are minimal. SD-OCT imaging of the affected retinal distribution in the acute phase will show inner and middle retinal hyper-reflectivity and thickening. The same distribution will appear thinned and atrophic in the chronic phase (Figure 3). Fluorescein angiogram may show absent or delayed perfusion distal to the occlusion. However, eventual reperfusion is common, and if blood flow has been restored, the angiogram may appear normal.



**Figure 3:** A. SD-OCT of a subacute central retinal artery occlusion showing inner and middle retinal hyper-reflectivity and thickening. B. SD-OCT of a chronic branch retinal artery occlusion in a second patient. Note the severe atrophy of the inner and middle retinal layers.

While anecdotal reports of successful restoration of blood flow after a variety of interventions exist, no treatment for acute retinal artery occlusion has been shown to improve visual outcomes. Inner retinal infarction likely occurs within minutes of complete arterial occlusion, and therefore any successful intervention must take place immediately. Minimally invasive strategies including ocular massage, rebreathing into a paper bag and anterior chamber paracentesis are often tried. More invasive intervention including, YAG laser disruption of the plaque, hyperbaric oxygen treatment and even catheter directed intra-arterial TPA are not frequently employed due to an unfavorable risk-benefit profile.

Although no evidence based ocular intervention exists for patients presenting with an acute retinal artery occlusion, the importance of systemic evaluation cannot be overstated. For patients presenting with central retinal artery or ophthalmic occlusion and symptoms consistent with giant cell arteritis (weight loss, headache, jaw claudication, proximal muscle weakness, temporal tenderness), inflammatory workup including ESR and CRP with rapid initiation of systemic steroids can prevent contralateral vision loss. More importantly, when an acute embolic retinal artery occlusion is suspected, immediate referral to a stroke center for head imaging and an exhaustive search for the embolic source is essential. Emboli most commonly originate from the internal carotid arteries, within the heart (as can result from atrial fibrillation), the aortic arch and less commonly from



calcified heart valves. Because emboli from these sources can also cause stroke, timely identification allows for immediate medical and surgical intervention which may prevent subsequent cerebral vascular accident. In our case, for instance, imaging and workup led to the diagnosis of an acute asymptomatic stroke and severe carotid occlusive disease. The patient underwent a carotid endarterectomy which may have prevented him from having a second, catastrophic stroke later.

Stroke and retinal artery occlusion is not an uncommon association. In fact, a recent study published in the American Journal of Ophthalmology found that 37.3% of patients presenting with acute CRAO had a coincident acute stroke found on imaging at the time of referral, 36.7% of patients had critical carotid occlusive disease, and 79% percent of patients had findings requiring hospitalization.<sup>1</sup> Other studies have found slightly lower, but also very significant stroke risk, most ranging from 20-25% over several years.<sup>2,3</sup> When these patients are identified early, surgical and medical interventions may be initiated that drastically reduce their risk. For this reason, it is the recommendation of the American Academy of Ophthalmology that all patients presenting with acute, symptomatic retinal artery occlusion be immediately referred for neurologic and cardiac workup at the closest stroke center. When a high degree of suspicion exists, these patients should not have confirmatory testing with a retina provider, and instead be sent directly to the closest stroke center. This timely intervention may save the patient's life.

1. Lavin, P., Patrylo, M., Hollar, M., Espaillet, K. B., Kirshner, H., & Schrag, M. (2018). Stroke Risk and Risk Factors in Patients With Central Retinal Artery Occlusion. American journal of ophthalmology, 196, 96-100.
2. Arnold, A. C. (2018). Urgent Evaluation of the Patient With Acute Central Retinal Artery Occlusion. American journal of ophthalmology, 196, xvi-xvii.
3. American Academy of Ophthalmology. (2016). Retinal and Ophthalmic Artery Occlusions Preferred Practice Patterns. Accessed from <https://www.aao.org/preferred-practice-pattern/retinal-ophthalmic-artery-occlusions-ppp-2016>

### Take Home Points

- Retinal artery occlusions present with highly variable visual symptoms and exam findings.
- Patients presenting with signs and symptoms of retinal ischemia have a high risk of coincident and subsequent cerebrovascular accident. Expedited referral to the emergency department of a stroke center enables the rapid identification of embolic sources and concurrent cardiac or cerebrovascular disease with rapid initiation of intervention for modifiable stroke risk factors.
- Chronic, asymptomatic artery occlusions require the same workup, but on an outpatient basis.
- The following link provides information on the locations of certified stroke centers:  
<https://www.stroke.org/understand-stroke/recognizing-stroke/emergency-stroke-center-locations/>



Thomas Hanscom



Robert Engstrom



Hajir Dadgostar



Amir Guerami



Christian Sanfilippo